

An Enhanced Method for Measuring the IMT by Segmenting the Carotid Artery Region

Ms. Mamatha U

Assistant Professor, Department of ECE, Don Bosco Institute of Technology, Bangalore, India.

Email: mamathau@gmail.com

Abstract—This paper offers with Ultrasound pictures of carotid artery are one of the parts that hard to recognize by inability specialist or radiologist on the grounds that the shape is verging on same like the muscle layer. Intima Media Thickness (IMT) of the common carotid artery (CCA) is a set up pointer of cardiovascular malady (CVD). Consequently, a carotid corridor programmed location strategy and programmed calculation for the division and estimation of the Intima Media Thickness (IMT) is proposed in this project. We suggest a computerized framework in Speckle reduction, segmentation and perform IMT estimations. The Region of Interest (ROI) parts (carotid artery layers) was extracted using cropping/masking and the segmented carotid artery region consists of multiple noises. Along with them the content of the speckle noise will be high. So with a particular end objective to evacuate the speckle we can utilize dot diminishment channel, for example, Speckle Reducing Anisotropic Diffusion (SRAD) filter. Keeping in mind the end objective to enhance the precision of portioning the carotid artery area, we perform Otsu thresholding calculation. The binarization was finished by utilizing Otsu's thresholding to section the carotid artery which was present very deeply in the ultrasound pictures. In the wake of applying binarization procedure and by performing morphological operations the carotid course district in the picture will be in improved structure, for example, it is simple for us to estimate the Intima Media Thickness (IMT). At long last the Upper and Lower Intima Media Thickness extent will be measured.

Index Terms— IMT, CCA, ROI, CVD, SRAD.

I. INTRODUCTION

Different studies have exhibited disparities between Intima Media Thickness (IMT) measured from left and right basic carotid courses (CCAs) by large and hypertensive populaces, which were credited to their disparities in vascular life structures and commanding pathologies. Be that as it may, whether this perception holds on among patients with known atherosclerotic sickness and whether the left and right CCA. The point of this study was to assess the side distinction in CCA IMT estimations [1]. In particular, expanded IMT associated increased danger mind dead tissue or cardiovascular assault. Thus evaluation of carotid divider status additionally vital distinguishing proof danger to patients. Customarily IMT measured manual depiction of intima and adventitia layers. Manual following of the lumen measurement and the IMT human specialist's generous experience, tedious, and results differ as indicated by the preparation, experience and judgment of specialists.

The main purpose of the projected project is finding the thickness of artery both the right and left sides of the male and female. Snake segmentation proposed in existing system [2]. And also in existing system not uses the correct filters to eliminate the noise that is also one of the main problems in the existing system. So from our proposed study gives best accurate result in the thickness measurement because in our project use the best filter operation and with the snake segmentation, we use the thresholding operation, binarization and also morphological operation.

II. METHODOLOGY

This paper proposes a Comparison plan of Ultrasound Intima Media Thickness Measurements of the right and left Common Carotid Artery. A novel multistep calculation is displayed enchanting account a blend of Automatic Region of Interest (ROI) discovery by utilizing editing, and binarization. With a specific end objective to expel the clamor we can utilize channels like lee, kuan and SRAD. In the wake of applying binarization strategy [4]. And by performing morphological operations the carotid conduit district in the image will be in upgraded structure. At long last the Upper and Lower Intima Media Thickness extent will be measured. The below Figure. 1 represents the block diagram of proposed system.

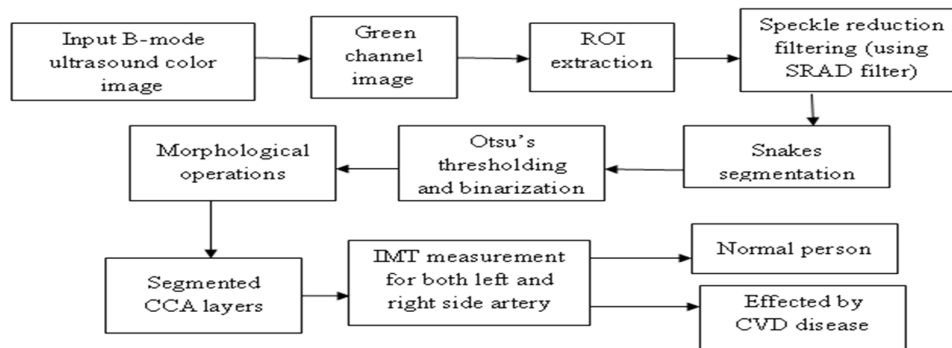


Figure 1. Block diagram of the proposed method

A. Ultra sound B-mode images

Ultrasound machine is a non-intrusive conclusion mama chine. It utilizes the high recurrence sound wave to catch the human internal self-perception. Dissimilar to other imaging modalities, the sound wave that transmits from the ultrasound machine test is protected to human body [6]. The sound wave make by ultrasound machine don't convey any reactions to human. The sound wave will experience human body and reflect back to the test once more. Nonetheless, distinctive sorts of tissue in human body will bring about the wave to reflect in various ways. After the test get the reflect signals, it will send to post handling framework to make a picture of human internal body.

B. ROI extraction

Area of interest (ROI) Extraction is one of the strides utilized as a part of fragmenting the carotid course divide in the given information picture which is totally unsupervised and was covered up in the given ultrasound picture .From the information picture, the required segment is trimmed and that edited picture is utilized for further process.

C. Speckle noise reduction filtering (SRAD)

The portioned carotid supply route area comprises of numerous commotions. Among them spot commotion substance will be high. So with a specific end goal to evacuate the commotion we can utilize channel like SRAD. The procedure of expelling the clamor content in the picture by utilizing channels is called De-dotting [5]. Spot NOISE: Speckle clamor is a granular commotion that inalienably exists in and corrupts the nature of ultrasound pictures. Spot clamor in routine radar results from irregular changes in the arrival signal from an item that is no greater than a solitary picture handling component. It expands the mean dim level of a neighborhood. SRAD is versatile and do not use hard limits to adjust execution in homogeneous districts or in locales close edges and little elements shown in equation (1) & (2).

$$\left\{ \begin{array}{l} \frac{\partial}{\partial t} I(x, y, t) = \text{div}(c(q) \cdot \nabla I(x, y, t)) \\ I(x, y, 0) = I_0(x, y), \frac{\partial I(x, y, t)}{\partial n} \partial \end{array} \right\} = 0 \dots\dots (1)$$

$$c(q) = \frac{1}{1 + \frac{[q^2(u,v,t) - q_0^2(t)]}{[q_0^2(t)(1 + q_0^2(t))]} \dots\dots\dots (2)$$

D. Segmentation

Division subdivides a picture addicted to its element area or item. Picture division strategies are arranged on the premise of two properties intermittence and similitude. Taking into account this property picture division is arranged as Edged based division and district based division. The result is a double picture. In view of hypothesis there are two primary edge based division strategies, dim histogram based and inclination based technique [3]. Locale based division segments a picture into districts that are comparative as stated by an arrangement of predefined criteria.

E. Morphological Operations

Subsequent to changing over the picture into binarized picture, evacuate each one of the pixels littler by utilizing morphological operations. In the morphological prepared picture, expel the openings happened between two lines. Morphological operations are influencing the structure, structure or state of an item. Linked on double pictures they are utilizing as a part of pre or post prepare or for getting a representation or depiction of the state of articles/districts.

F. Estimation of Intima Media Thickness (IMT)

Measure upper side and lower side of right and left side of the carotid artery. The estimation is generally made by outside ultrasound, periodically by inner, obtrusive ultrasound catheters.

III. RESULTS

These images are original patient ultrasound image. The image acquisition technique generates large ultrasound photos. The Ultrasound pictures of the common Carotid Artery (CCA) of a few patients are captured. Figure. 2 show normal person image & Figure 3. Shows the CVD persons ultrasound image.

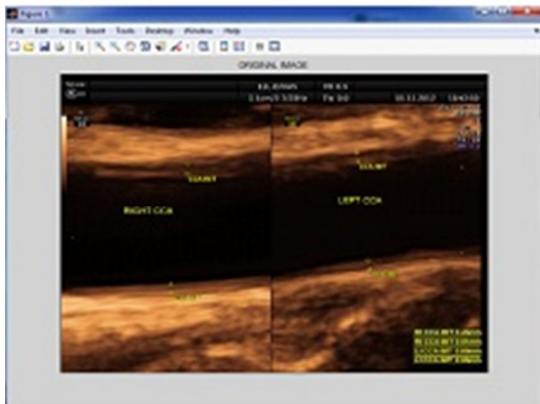


Figure 2. Normal person ultrasound image

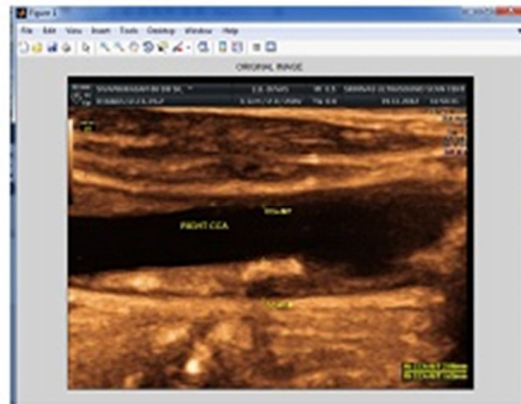


Figure 3. CVD person ultrasound image

The captured pictures are converted into gray scale photograph if it is in RGB (coloration) form. Then this ultrasound color image converted into green channel image. Because ultrasound color image is more responsive to the human eye.

From the input photograph, the required component is cropped and that cropped image is used for in addition manner. Figure 4 and Figure 5 shows the LEE and KUAN filtered image existed filtering techniques.

Snakes are used for discovering remarkable picture shapes. If more than imply price then its '1' in any other case its '0'. Thresholding is best segmentation From a gray scale picture, thresholding may be used to create

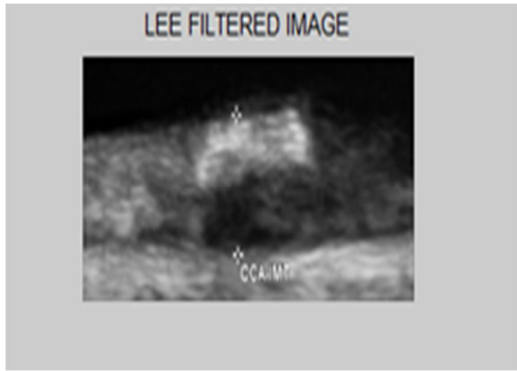


Figure 4. CVD person LEE filtered image

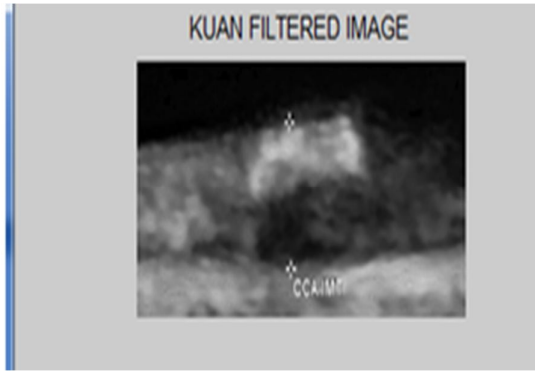


Figure 5. CVD person KAUN filtered

binary pictures. After converting the photograph into binarised image, do away with all the pixels smaller by using morphological operations.

Morphological operations are influencing the structure, structure or state of an item. Connected on double pictures (dark and white pictures – Images with just 2 hues: high contrast). They utilize as a part of pre or post preparing (sifting, diminishing, and pruning) or for getting a representation or depiction of the state of articles/districts. Image segmentation is a significant part in photo processing. The unwanted part in the image can be removed by erosion. Inside the morphological processed photo, dispose of the holes came about between two lines. Filling holes between two lines using white pixel called dilation. Figure 6 and Figure 7 shows the Normal person & CVD person carotid artery image.




Figure 6 Normal person carotid artery image




Figure 7. CVD person carotid artery image

The below Table I shows the filter specification of normal person and CVD person. This shows the projected system filter perform is enhanced than exist filter.

TABLE I. COMPARISON OF DIFFERENT FILTER PERFORMANCE

Filters\Parameters	PSNR	MSE	NCC
LEE(normal)	35.38	18.824	0.975
KUAN (normal)	37.41	11.78	0.956
SRAD (normal)	47.86	1.064	0.158
LEE (CVD)	38.69	8.788	0.993
KUAN(CVD)	36.30	15.21	0.991
SRAD(CVD)	47.59	1.1302	0.214

IV. CONCLUSION

Ultrasound pictures of carotid course are one of the parts that were complicated to differentiate by the naïveté specialists or radiologist in light of the reality that the shape is practically same like the muscle layer. Subsequently, a carotid conduit programmed recognition technique is proposed for the division and the estimation of the Intima Media Thickness (IMT) is additionally proposed in this study. The general strategy for sectioning the carotid course has been fruitful created utilizing MATLAB to consequently recognize the carotid supply route from ultrasound pictures. The outcomes will help the specialists and radiologist for further determination. Other than that, the patient can get the right prior treatment and the possibility of recuperation is expanded. This strategy is useful for patients, in light of the information that from this technique we give an early treatment to patients furthermore safe from the heart assault and stroke. This automated strategy gives the precise estimation in thickness that likewise accommodating for patients and doctors to take next activities.

REFERENCES

- [1] P. Pignoli, E. Tremoli, A. Poli, P. Oreste, and R. Paoletti, "Intima plus media thickness of the arterial wall: A direct measurement with ultrasound imaging," *Atheroscl.*, vol. 74, no. 6, pp. 1399–1406, 1986.
- [2] P.-J. Touboul, J. Labreuche, E. Vicaud, and P. Amarenco, "Carotid intima-media thickness, plaques, and Framingham risk score as independent determinants of stroke risk," *Stroke*, vol. 36, no. 8, pp. 1741–1745, 2005.
- [3] T. Watanabe, S. Koba, M. Kawamura, M. Itokawa, T. Idei, Y. Nakagawa, T. Iguchi, and T. Katagiri, "Small dense low-density lipoprotein and carotid atherosclerosis in relation to vascular dementia," *Metabolism*, vol. 53, no. 4, pp. 476–482, 2004.
- [4] C. P. Loizou, C. S. Pattichis, M. S. Pantziaris, T. Tyllis, and A.N. Nicolaides, "Snakes based segmentation of the common carotid artery intima media," *Med. Biol. Eng. Comput.*, vol. 45, pp. 35–49, Jan. 2007.
- [5] Magyar MT, Szikszai Z, Balla J, et al: Early onset carotid atherosclerosis associated with increased intima media thickness and elevated serum levels of inflammatory markers. *Stroke* 2003; 34: 58–63.
- [6] Luedemann J, Schminke U, Berger K, et al: Association between behavior-dependent cardiovascular risk factors and asymptomatic carotid atherosclerosis in a general population. *Stroke* 2002; 33: 2929–2935.